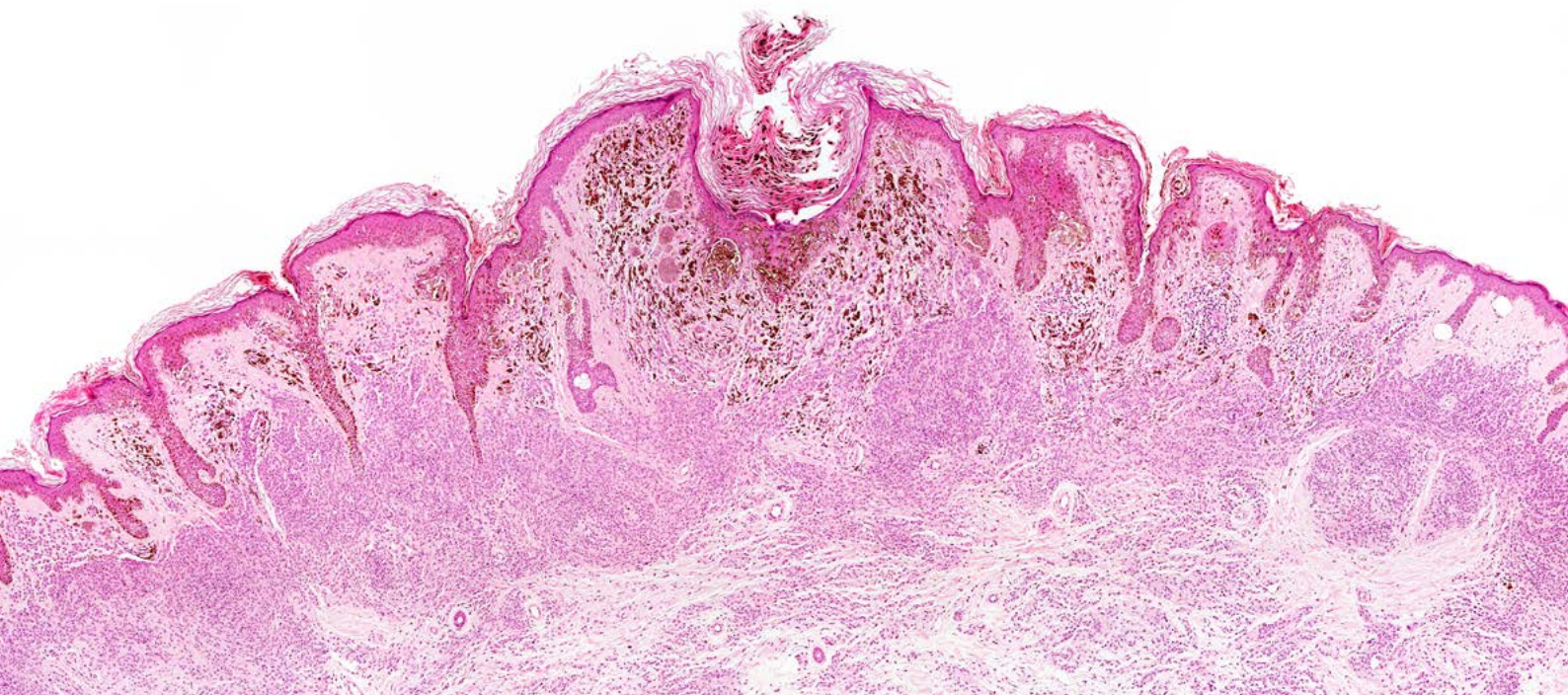


PATHOLOGY FOCUS

February 2020 | Skin Cancer Edition | Medical Newsletter 10

Featured articles:

- Suspicious Pigmented Skin Lesions - Melanoma and Dysplastic Naevi
- GP Connect Interview on Skin Cancer
- The Importance of Holter Monitors in the Identification of Cardiac Arrhythmias



Suspicious Pigmented Skin Lesions - Melanoma and Dysplastic Naevi

By Dr Jenny Grew and Dr Janez Cernecl

Australia and New Zealand have the highest incidence of melanoma in the world. Atypical pigmented skin lesions are therefore a common clinical presentation. This article aims to highlight some of the important recommendations from two recent publications, the Cancer Council guidelines for the diagnosis and management of melanoma (wiki.cancer.org.au)* and the WHO Classification of Skin Tumours (2018).

**First update since 2008, now in electronic "wiki" format for ease of updates as new evidence becomes available in this era of rapid advances.*

Melanoma is a malignancy of melanocytes, the pigment-producing cells of the skin and mucosa. Most cutaneous melanomas are caused by mutations and molecular events as a result of ultraviolet irradiation.

Melanoma continues to be a significant public health concern in Australia, responsible for significant morbidity and mortality.

There are 13,000 new cases of melanoma and over 1,750 deaths each year. It is the commonest cause of cancer and cancer deaths in young adults and the third most common cancer in older adults.

CLASSIFICATION OF MELANOMA

Melanoma subtypes differ depending on whether they occur on intermittently or chronically sun-exposed skin or in sun-shielded sites.

Melanomas arising in sun-exposed skin

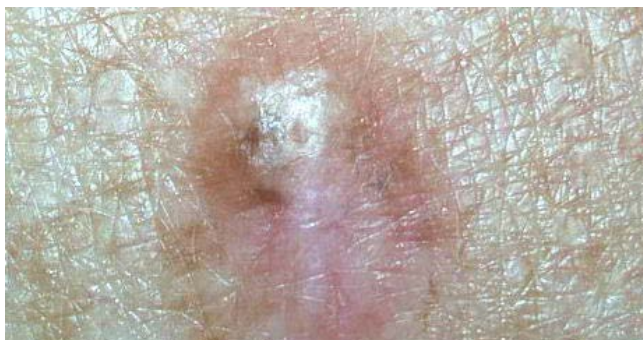Low degree of cumulative sun damage (CSD)

- Superficial spreading melanoma
- Nodular melanoma subset

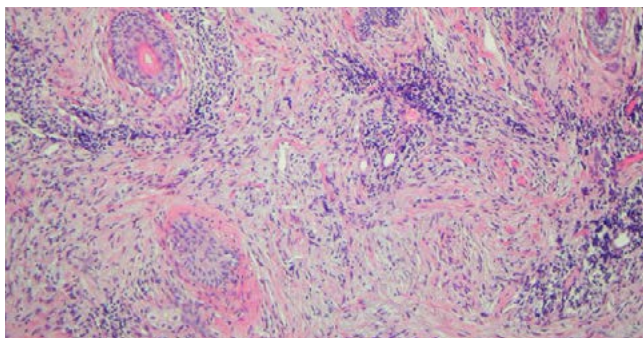
High degree of cumulative sun damage

- Lentigo maligna
- Nodular melanoma subset

Desmoplastic melanoma



Desmoplastic melanoma – clinical appearance.



Desmoplastic melanoma – histology. Note spindle cells extending around hair follicles in the dermis. Tumour-infiltrating lymphocytes are prominent.

Melanomas arising at **sun-shielded sites** or without known aetiological associations with UV radiation exposure include acral, mucosal and uveal types and those arising in congenital naevi and blue naevi.

MAKING THE DIAGNOSIS - WHAT TYPE OF BIOPSY?

Many different pigmented skin lesions may be encountered in general and specialist dermatology practice.

For example:

- Increased melanin pigmentation, but no melanocytic proliferation - post-inflammatory pigment alteration, ephelis (freckle), labial melanotic macule;
- Pigmented epithelial proliferations - seborrhoeic keratosis, solar lentigo;
- Melanocytic proliferations - simple lentigo, naevi and melanoma.

In the clinical presentation of an atypical pigmented lesion, a **biopsy** is usually required to distinguish between a melanoma and benign mimics, including *dysplastic naevi* (see page 4 for information on *dysplastic naevi*).

Complete excisional biopsies

Elliptical excision and primary closure: complete excision with a 2mm margin is the ideal method for suspicious pigmented skin lesions.

Why is complete elliptical excision the best excision method for these lesions?

- Melanocytic lesions are heterogenous. Diagnostic changes of melanoma may be missed by partial sampling, especially punch biopsy.
- Assessment of size, symmetry and circumscription, required for assessment of melanocytic lesions, is difficult or impossible in a partial sample - especially in the absence of clinical information regarding lesion size and intent of sample (see page 3 for Clinical Information).
- Breslow thickness, which guides management and prognostication, is only accurately determined on examination of the entire intact lesion.

Deep shave excision: also known as 'saucerisation'.

- Aims to completely remove the lesion at peripheries and in depth.
- May be warranted in low suspicion lesions on trunk and proximal extremities, if palpation does not suggest deeper dermal extension.
- More often associated with positive margins than elliptical excision.

Circumstances where other biopsy types may be appropriate

Broad lesions on the face: shave or incisional biopsy (e.g. *lentigo maligna melanoma* - see information panel on the right).

Large lesions at other sites, functionally sensitive sites (such as the sole of the foot): consider punch or incisional biopsy to confirm diagnosis prior to definitive treatment.

EXCISION MARGINS: WHAT ARE THE RECOMMENDATIONS?

Radial excision margins, measured from the edge of the melanoma, as below:

pT1 melanoma < 1.0mm	1 cm
pT2 melanoma 1.01 mm - 2.0 mm	1-2 cm
pT3 melanoma 2.01 mm - 4.00 mm	1-2 cm
pT4 melanoma > 4.0 mm	2 cm

Depth: down to but not including the deep fascia, unless it is involved or has been reached during the diagnostic excision.

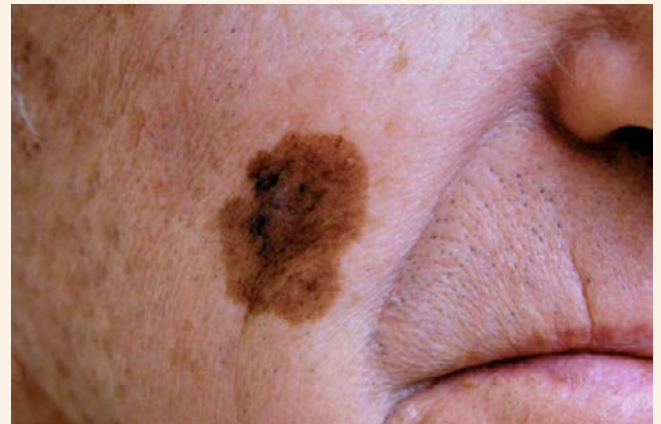If subcutis is particularly deep, excise to depth equal to the recommended lateral excision margin.

What clinical information should be given to the pathologist evaluating a suspicious pigmented lesion?

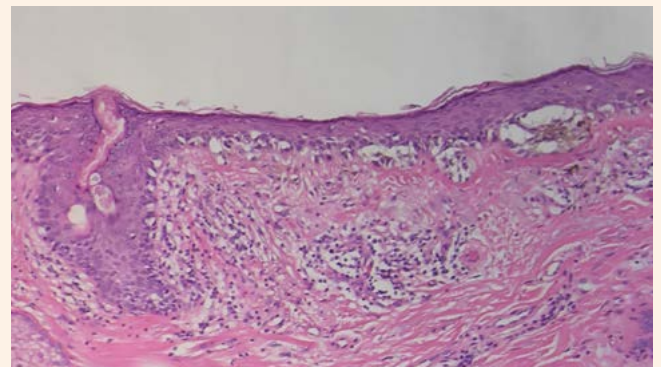
- Specimen type, laterality, orientation
- For re-excision specimens: previous laboratory, lab accession number and findings in previous biopsy
- Clinical diagnosis or differential diagnosis
- History of current lesion: duration, duration/tempo of change, size, ulceration
- Any clinically or dermatoscopically suspicious areas?
- History and timing of lesional trauma, biopsy, irritation, treatment with topical agent, laser, radiation therapy
- Past history of melanoma?
- Evidence of current or previous metastatic disease?
- Other relevant history: family history of melanoma or dysplastic naevus syndrome, current or recent pregnancy



Lentigo maligna melanoma (LMM) is associated with a high degree of cumulative sun damage, characterised histologically by a lentiginous in situ component called lentigo maligna, also sometimes called LMM in situ.



Lentigo maligna – clinical appearance.



Lentigo maligna – histology.

Note prominent solar elastosis, effaced rete and cytologically atypical basal melanocytes.

These lesions typically occur on the face as a large patch/plaque with mottled areas of different colours. These polymorphous areas represent a mixture and collision of melanocytic and pigmented non-melanocytic lesions, with regression contributing to the overall variegated appearance. Histologically, the melanocytic areas are often variable, comprising an atypical lentiginous melanocytic proliferation that transitions into areas of in situ melanoma or even invasive melanoma. The superimposed non-melanocytic lesions may include seborrhoeic keratosis, solar lentigo, pigmented solar keratosis and intraepidermal carcinoma.

Partial biopsy of lentigo maligna melanoma is therefore prone to under-diagnosis. Instead, *multiple shave biopsies to sample each different area/colour* should be performed if complete excision is not feasible.

Shave biopsies are preferred over punches, as width rather than depth is more helpful diagnostically and are more acceptable for healing and cosmesis.

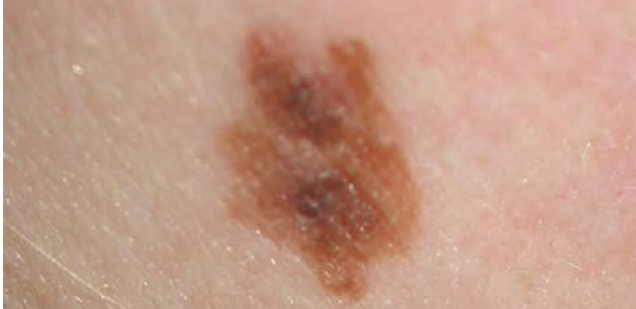DYSPLASTIC NAEVI

Clinical:

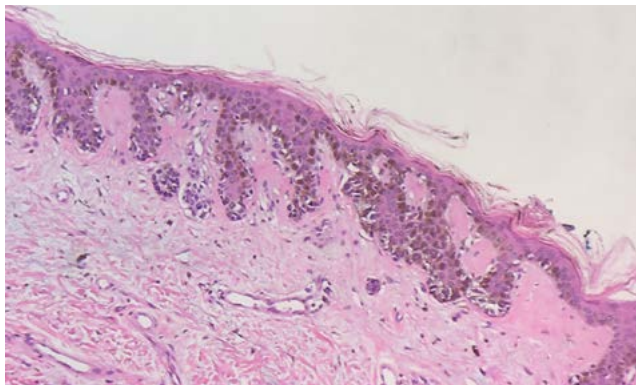
- Atypical
- Macular (flat) component in at least one area and exhibiting at least three of the following features:
 - ✓ Ill-defined border
 - ✓ Uneven periphery
 - ✓ Size at least 5mm
 - ✓ Erythema
 - ✓ Colour variegation

Histology:

- Architectural disorder
- Cytological atypia



Dysplastic naevus – clinical appearance. The lesion is more than 5mm in diameter.



Dysplastic naevus – histology. Note the architectural features including elongated rete with lamellar fibroplasia. There are also haphazardly located, variably-sized junctional nests of melanocytes which show at least moderate cytological atypia.

Clinical, histologic and genomic features indicate that dysplastic naevi are intermediate between common acquired naevi and in situ melanoma.

The 2018 WHO Classification of Skin Tumours

has removed the entity of ‘mildly dysplastic naevus’ and instead recommends using only two grades of dysplasia: LOW-GRADE and HIGH-GRADE dysplasia.

WHO Classification (2018)	Former Grade
Not a dysplastic naevus	Mild dysplasia
Low-grade dysplasia	Moderate dysplasia
High-grade dysplasia	Severe dysplasia

Significance of dysplastic naevi

1. Morphologic mimic of melanoma
2. Potential melanoma precursor
3. Biomarker for increased melanoma risk

To re-excise or not?

Dysplastic naevi are much more common than melanoma and the risk of progression of any given lesion is low. However, for **high-grade dysplastic naevi** with positive histologic margins, re-excision with a 2-5mm clinical clearance is recommended. If margins are clear but narrowly so (< 2mm), there is currently no clear consensus regarding re-excision.

Low-grade dysplastic naevi

Where there are clear histologic margins and no pigment evident clinically, re-excision is not required, unless there was a high level of clinical concern pre-biopsy. Positive histologic margins: re-excision may not be required, if margins were clinically clear and there is no residual pigment. Observation in this setting remains controversial and is not uniformly accepted clinical practice.

What has become of the formerly known ‘mildly dysplastic naevus’?

These are lentiginous naevi - pigmented lesions that have the appearance of simple lentigo with the addition of one or more small nests of melanocytes. There may be architectural features of dysplastic naevus but these are small lesions with, at most, mild cytological atypia. These lesions are not associated with an increased risk of melanoma and are very common in the general population.

About the authors



Dr Jenny Grew

MBChB, FRCPA, AFRACMA

Lab: Subiaco

Areas Of Interest: Breast, gastrointestinal, gynaecological & cutaneous pathology, cytology and molecular pathology

Speciality: Anatomical Pathology

Phone: (08) 9213 2175

Email: jenny.grew@clinicallabs.com.au

A graduate of the University of Otago in 1992, Dr Jenny Grew began pathology training at Christchurch Hospital (NZ), gaining fellowship of the Royal College of Pathologists in 2001. Jenny worked in a breast screen accredited lab for 7 years in NZ, and attended the pre-operative diagnostic Nottingham breast course. In 2007 she moved from New Zealand to Queensland, taking up the role of Pathologist in Charge at QML Pathology, providing service to 6 public and private hospitals on the Sunshine Coast. In 2017, Jenny moved to Western Australian and joined Australian Clinical Labs WA as Clinical Director of Anatomical Pathology.



GP Connect is an initiative to facilitate a broader understanding of laboratory testing by focusing on common enquires between General Practitioners and Pathologists at Australian Clinical Labs.

In this edition, Skin Cancer Practitioner Dr Emily Shaw asks Clinical Labs Anatomical Pathologist, Dr Gabriel Scripcaru, a series of questions to promote discussion between general practitioners and pathologists to optimise skin cancer management.



Dr Gabriel Scripcaru

(Pathologist – Australian Clinical Labs, Clayton)

FRCPA, MD

Speciality: Anatomical Pathology

Areas Of Interest: Skin Pathology, Head, Neck & Soft Tissue Pathology

Phone: 1300 134 111

Email: gabriel.scripcaru@clinicallabs.com.au

Prior to training in anatomical pathology, Dr Gabriel Scripcaru trained in surgery and obtained a membership of The Royal College of Surgeons of Edinburgh (RCSEd). Dr Scripcaru's training in anatomical pathology included rotations at the The Royal Melbourne Hospital, The Royal Women's and The Royal Children's hospitals in Melbourne. Before joining Australian Clinical Labs, Dr Scripcaru worked at Southern Sun Pathology in Sydney where he gained experience in dermatopathology.



Dr Emily Shaw

(Skin Cancer Practitioner - Western Skin Institute, Warrn Ponds and Colac)

MBBS(Hon 1), FRACGP, Advanced Certificate in Skin Cancer Medicine, Surgery and Dermatoscopy

Dr Emily Shaw is a full time skin cancer practitioner, working at Western Skin Institute in their Warrn Ponds and Colac clinics. She works under Medical Director, Dr Eugene Tan, specialist Dermatologist and Fellowship accredited Mohs Surgeon, based at the St Albans clinic. Dr Shaw is passionate about ongoing education and is actively involved in GP registrar and medical student teaching. She strongly believes in a collaborative medical approach to patient care and that in skin cancer management, a clinical-pathological correlation is extremely important.

Dr Emily Shaw (Skin Cancer Practitioner)

Can you explain what a basosquamous carcinoma is and what the patient implications are for this diagnosis?

Dr Gabriel Scripcaru (Pathologist)

A basosquamous carcinoma is essentially a variant of moderately differentiated squamous cell carcinoma (SCC) including some areas of basaloid differentiation. It has a propensity to lymphovascular invasion, as opposed to a basal cell carcinoma (BCC) or a well differentiated SCC.

The management, staging and follow up should be those of a moderately differentiated SCC.

The diagnostic pitfall, if inadequately sampled (e.g. punch biopsy), is that it may be misdiagnosed as a BCC.

Dr Emily Shaw (Skin Cancer Practitioner)

When we are considering management of an SCC, there are both patient factors as well as histological features in determining a high risk state. Can you explain the histological features which are considered high risk in an SCC?

Dr Gabriel Scripcaru (Pathologist)

High risk histological factors in SCC consist of the following:

1. Low degree of differentiation: increased cytological atypia and nuclear pleomorphism.
2. Degree of keratinisation: reduced or absent keratinisation.
3. Proliferative index: increased mitotic count and presence of atypical mitotic forms.
4. Architectural pattern: highly infiltrative pattern.
5. Presence of lymphovascular or perineural invasion.
6. Certain types of differentiation of the malignant cells: spindle cell/sarcomatoid, basaloid/basosquamous, adenosquamous and desmoplastic.

Dr Emily Shaw (Skin Cancer Practitioner)

Curettage is often a treatment option for some superficial skin cancers. Can you explain the limitation in receiving curetted tissue fragments versus a shave/saucerisation for interpretation?

Dr Gabriel Scripcaru (Pathologist)

Curettage is an adequate procedure in certain clinical scenarios, however, it poses some limitations concerning the histological assessment of the tissue received.

The interpretation of curetted lesions may be hampered by fragmentation of the tissue examined. Fragmentation precludes accurate assessment of the architecture of the lesion. The variable size and multitude of the tissue fragments prevents orientation during embedding and sectioning of the blocks prior to staining of the slides. This leads to inadvertent tangential sectioning. Visualisation of the basal aspect of epithelial structures may mimic lack of “cytological maturation” hence falsely raising suspicion of malignancy.

In addition, crush, cutting or staining artefacts are more likely in fragmented, curetted material.

The pathologist bears in mind all these pitfalls when interpreting curetted specimens. The report and final conclusion may be more guarded when, due to the above mentioned reasons, the presence or absence of a lesion cannot be unequivocally proven or excluded.

Dr Emily Shaw (Skin Cancer Practitioner)

Can you discuss specimen orientation and the implications of a report stating e.g. positive at the 3 o'clock margin?

Dr Gabriel Scripcaru (Pathologist)

Orientation should be attempted only on excisional specimens that are usually elliptical, ovoid or triangular in shape. Orientation of shave and punch biopsies is inadequate and should not be employed.

For clinical reasons, such as wound healing and pathological interpretation, the excisional specimen should have, where possible, a long axis. This is the reason why the most common excisional specimen is ovoid or elliptical.

The orientation allows the pathologist to measure the distance to the respective side of the imaginary clock. A positive 3 o'clock margin should be read as “the lesion extends to the margin along the 12-3-6 side of the clock”. This may coincide with the 3 o'clock point, but it may be closer to 2 or 4 o'clock. In most specimens it is neither practical, reliable or beneficial to attempt a more detailed description of the margin, as re-excision along the entire involved quadrants of the clock should be employed.

In rare cases, when the specimen is very large and several slices are obtained of which only a small area is involved, a more detailed estimate, such as “3 o'clock towards the 6 o'clock tip of the ellipse” may be given. In this case it allows for a smaller re-excision specimen centred around the previously involved margin.

Dr Emily Shaw (Skin Cancer Practitioner)

Do you find receiving dermoscopic images helpful for slide interpretation?

Dr Gabriel Scripcaru (Pathologist)

Yes, especially in difficult cases or cases where the clinical impression and histological findings do not readily concur. Seeing the dermoscopic image may help in explaining diagnostic conundrums and making a better, more informed diagnosis.

Dr Emily Shaw (Skin Cancer Practitioner)

I understand that pigmented skin lesions can, at times, be difficult to interpret. As clinicians, what can we do to assist?

Dr Gabriel Scripcaru (Pathologist)

In pigmented lesions, more than in any other neoplastic skin lesions, accurate and detailed clinical information is relevant.

Aspects ideally included are:

- Site of lesion, age of lesion (approximate time of onset), recent change (at clinical routine follow up or noted by patient)
- Clinical description of the lesion, dermoscopic findings
- Previous biopsy, local trauma, symptoms noted by the patient in regards to the respective lesion

Dr Emily Shaw (Skin Cancer Practitioner)

What is the preferred type of biopsy for a melanocytic lesion?

Dr Gabriel Scripcaru (Pathologist)

For melanocytic lesions, the general rule should be attempting to remove the entire lesion, hence a punch biopsy through the lesion is not adequate.

This is due to the fact that a sampled fragment of the lesion does not allow assessment of the architecture and may not be representative of the entire lesion.

A punch biopsy is only acceptable if the lesion is small and the punch biopsy is broad and excisional.

The preferred method is ideally an excisional skin ellipse or a thick shave biopsy which allows assessment of the architecture.

Local skin pathologist near you



Dr Predrag Nikolic

MBChB, MMedSci, PhD, FRCPA

Lab: Clayton

Areas Of Interest: Skin Pathology, Lung Pathology, Breast Pathology, Molecular Diagnostics

Speciality: Anatomical Pathology

Phone: 1300 134 111

Email: predrag.nikolic@clinicallabs.com.au

Holter Monitors and their Importance in the Identification of Cardiac Arrhythmias

By Associate Professor Harry G Mond OAM

Since its introduction as a clinical investigative tool, the 12-lead electrocardiograph (ECG) has been the gold standard for recognition of cardiac arrhythmias. The resting 12-lead ECG, however, only gives a rhythm snapshot in time, whereas arrhythmias may be short-lived, paroxysmal and even asymptomatic, making documentation in many patients very difficult.

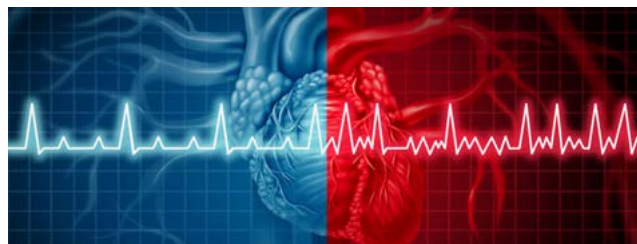Ambulatory ECG monitoring has been developed as a means of recording the ECG over a set period of time in patients suspected of having cardiac arrhythmias.

ARRHYTHMIA INDICATIONS FOR AMBULATORY ECG MONITORING

A Holter monitor is preferable to all other monitoring as it provides a 24-hour window of the heart rate changes and can be partnered to symptoms.

- **Cardiac palpitations**
This is by far the most common indication for ambulatory ECG monitoring. Generally, a Holter monitor is performed even when symptoms are infrequent.
- **Unexplained syncope or dizziness**
This is a very important group. If symptoms are frequent such as daily dizziness, Holter monitoring is very useful and is generally the initial investigation in patients even with relatively infrequent episodes.
- **Suspected slow heart rhythms**
Holter monitoring remains the most important investigation in the evaluation of symptomatic patients who are being assessed for pacemaker implantation.
- **Hereditary “electrical” abnormalities**
This diverse group involves a number of hereditary abnormalities associated with cardiac arrhythmias. The most common is Wolff-Parkinson White syndrome manifested by an accessory pathway, ventricular pre-excitation and atrioventricular re-entrant tachycardia.
- **Evaluate the abnormal ECG; ectopy and heart block**
- **Cryptogenic stroke evaluation to document paroxysmal atrial fibrillation**
- **Evaluation of success of either antiarrhythmic or ablative therapy**
- **Evaluation of ventricular tachycardia**
- **Paediatric monitoring**
- **Following acute myocardial infarction**

- **Potentially lethal arrhythmias with congestive and hypertrophic cardiomyopathy**
- **Monitor cardiac implantable electronic device therapy**
- **Chest pain or dyspnoea thought to be associated with arrhythmias**



The role of GPs in cardiac testing

Cardiologists prefer that patients presenting with the common warning signs discussed above – palpitations, unexplained dizziness, slow heart rhythms – undertake Holter monitor testing from their GP before they are referred on. The patient can undertake the Holter test as they wait to see a cardiologist. Then the cardiologist already has the data and results on-hand when the patient sees them. This will shorten the diagnostic process, allowing the cardiologist to make the most informed decision from the outset.

MONITORING HARDWARE

The most frequently used hardware is the 24-hour Holter monitor. Current models are now small and light and carried around the neck, on a belt or in the pocket, have a patient actuated button for event recording, and are battery operated.



Holter Monitor Service Available at Clinical Labs

DATA ANALYSIS

The major function of ambulatory ECG monitoring is to document an abnormality in cardiac rhythm.

Data analysis is completed by the following steps

1. Once your patient has finished with their 24-hour Holter monitor and returned the monitor to the collection centre, the monitor is then sent to the nearest Clinical Labs laboratory where the recorded data is retrieved from the memory card and sent to CardioScan (Holter monitors ordered through Clinical Labs are supplied by CardioScan).
2. The raw data is then computer-scanned by CardioScan technicians trained to recognise abnormal ECG patterns.
3. Once it is determined that the study is of satisfactory quality, it is then analysed and a report is generated.
4. The final report is then confirmed by an experienced CardioScan cardiologist, returned to Clinical Labs and sent on to the referring doctor.

REPORT INTERPRETATION

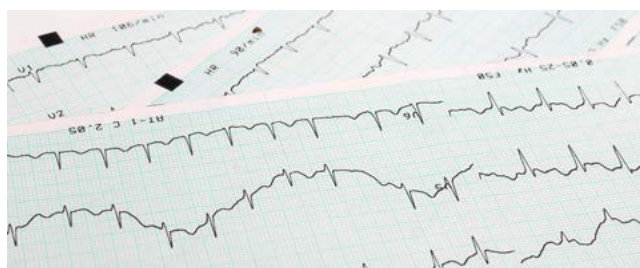The most important information from the Holter monitor report is contained in the Summary Page.

This includes:

- Summary of the 24-hour study and significant events
- Cardiologist conclusion

For the reporting physician, there is a minimal knowledge requirement for competency in interpreting ambulatory ECG monitoring reports.

For more information on Ambulatory Electrocardiographic Monitoring see Associate Professor Harry G Mond's article 'The Spectrum of Ambulatory Electrocardiographic Monitoring' published in Heart, Lung and Circulation (2017) 26, 1160–1174.



About the author



Associate Professor Harry G Mond OAM

MD, PhD, FRACP, FACC, FCSANZ

Medical Director CardioScan Pty Ltd

Dr Harry Mond is an Associate Professor at both the University of Melbourne and Monash University. After training at The Royal Melbourne Hospital and in Atlanta Georgia, he has been practicing as a Cardiologist in Melbourne since 1975. He is Australia's leading expert in cardiac pacing with extensive experience in pacemaker implantation and follow-up.

How to order Holter monitor testing at Clinical Labs:

1. Complete a **Clinical Labs referral form** and request **24-hour Holter monitor**.
2. Patients will need to book an appointment at their closest Clinical Labs collection centre to have the Holter monitor fitted. The easiest way for them to do this is to visit the Clinical Labs website clinicallabs.com.au/location type in their postcode and select 'Holter monitor', pick collection centre and call the number listed.
3. Patient's will be charged an **out-of-pocket fee of \$40** for the Holter monitor service (no out-of-pocket fee for pensioners/health care card holders).

NB: Your patient's Holter monitor report will be available within 5 business days from the return of the Holter monitor to the Clinical Labs Collection Centre.

To receive our bi-monthly clinical newsletter, updates, educational resources and more, go to clinicallabs.com.au/subscribe and follow the instructions.

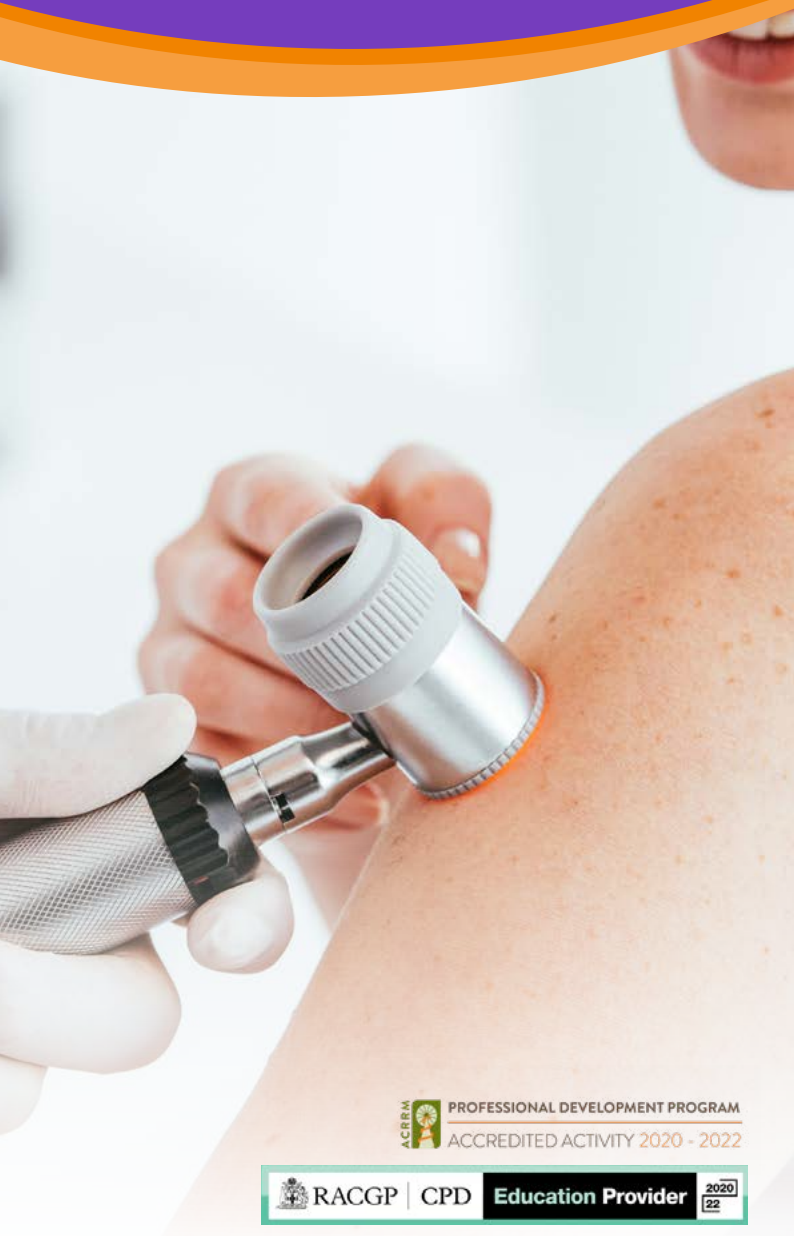

2020-2022 TRIENNIUM



Skin Excision Evaluation Program

Join thousands of general practitioners nationwide and earn your CPD points while improving your clinical skills

To start the registration process email your CPD number and practice address to skinaudit@clinicalabs.com.au today



 PROFESSIONAL DEVELOPMENT PROGRAM
ACCREDITED ACTIVITY 2020 - 2022

 RACGP | CPD Education Provider 

Subscribe to our electronic mailing list

Subscribe to the Clinical Labs mailing list and receive our bi-monthly clinical newsletter, important updates, educational resources and more, delivered directly to your inbox. Simply visit clinicallabs.com.au/subscribe and follow the instructions.

Alternatively, complete the form below, tear along the perforated edge and fax it to Clinical Labs Head Office on **(03) 9538 6733**

Title

Given Name

Surname

Email

Practice Name

Practice Address

Practice Suburb

Post Code

Please tick one of the below:

- General Practitioner
- Specialist
- Medical Centre / Practice Manager

Thank you